

Letter to Editor

Marathon despite unilateral vocal fold paralysis

Dear Editor-in-chief,

The principal symptoms of unilateral vocal fold paralysis are hoarseness and difficulty in swallowing. Dyspnea is comparatively rare (Laccourreye et al., 2003). The extent to which unilateral vocal fold paralysis may lead to respiratory problems at all – in contrast to bilateral vocal fold paralysis- has not yet well been determined. On the one hand, inspiration is impaired with unilateral vocal fold paralysis; on the other hand, neither the position of the vocal fold paralysis nor the degree of breathiness correlates with respiratory parameters (Cantarella et al., 2003; 2005). The question of what respiratory stress a patient with a vocal fold paresis can endure has not yet been dealt with.

A 43 year-old female patient was suffering from recurrent unspecific respiratory complaints for four months after physical activity. During training for a marathon, she experienced no difficulty in breathing. These unspecific respiratory complaints occurred only after athletic activity and persisted for hours. The patient observed neither an increased coughing nor a stridor. Her voice remained unaltered during the attacks, nor were there any signs of a symptomatic gastroesophageal reflux or infectious disease. A cardio-pulmonary and a radiological examination by means of an X-ray of the thorax also revealed no pathological phenomena. As antiallergic and antiobstructive therapy remained unsuccessful, a laryngological examination was performed in order to exclude a vocal cord dysfunction.

Surprisingly enough, the laryngostroboscopy showed, as an initial description, a vocal fold paralysis of the left vocal fold in median position (Figure 1). The anamnestic background for the cause was unclear. The only clue was a thoracotomy on the left side due to a pleuritis in childhood. A subsequent laryngoscopic ex-

amination had never been performed. Good mucosa waves and amplitudes were shown bilateral with complete glottal closure. Neither in the acoustic analysis, nor in the physical analysis conspicuous results were shown concerning hoarseness, shimmer or jitter. The maximum-phonation-time was slightly restricted at 11 seconds. Both vocal dynamics and frequency spectrum showed normal ratings.

Neck CT and thorax region MRT were performed, showing no pathology in the area of the recurrent nerve or the vagus.

The patient was re-examined at the Clinic for Sports Medicine on the basis of the laryngological results. Neither in the internal sports medical examination nor in the physical analysis were conspicuous results shown. The flow characteristics registered breath-by-breath during the ergometry (bicycle- ergometry up to 125 W) were completely unaffected up to maximal ventilation (Figure 2). The blood gases after exertion and the performance attained showed norm ratings.

Two months after the examination the patient ran her first marathon. No respiratory complaints were experienced any more.

Although there is one description of dyspnea due to a unilateral vocal fold paralysis published (Laccourreye et al., 2003), there are still no data regarding either the form of stress that goes together with laryngeally caused dyspnea or what mechanism induces it. Both restriction of the breath cross-section and excessively high consumption of air during phonation may produce a subjective sensation of unspecific respiratory complaints. It was shown that, in vocal fold paralysis, inspirational flow is in fact reduced – in contrast to expiratory flow (Beaty and Hoffman, 1999; Cantarella et al., 2003). However, neither the position of the fixed vocal fold nor the degree of breathiness had an influence on the breathing parameters (Cantarella et al.,

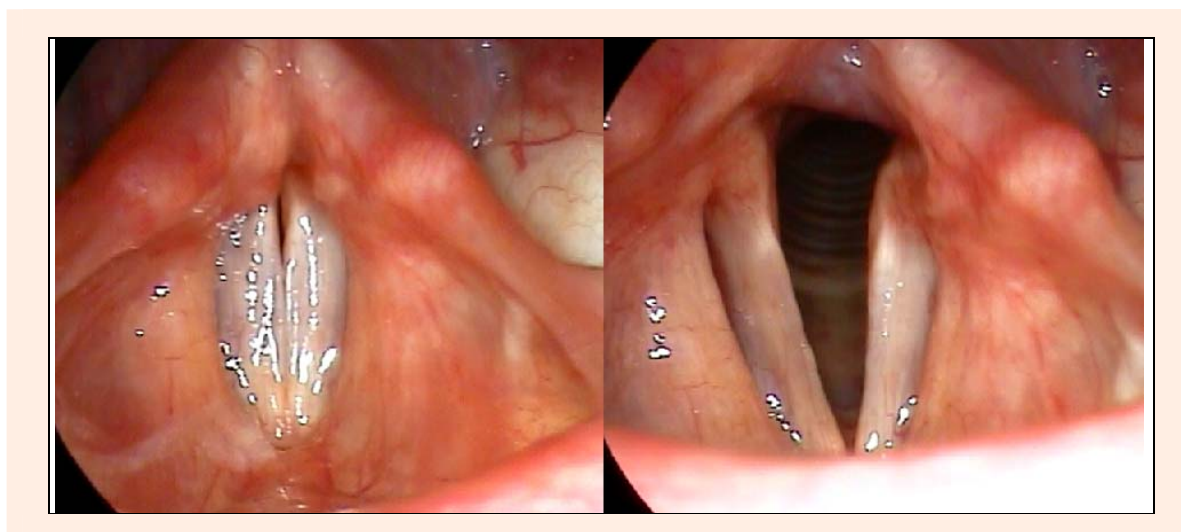


Figure 1. Indirect laryngoscopy: phonation position with complete glottal closure (left) and respiratory position (right)

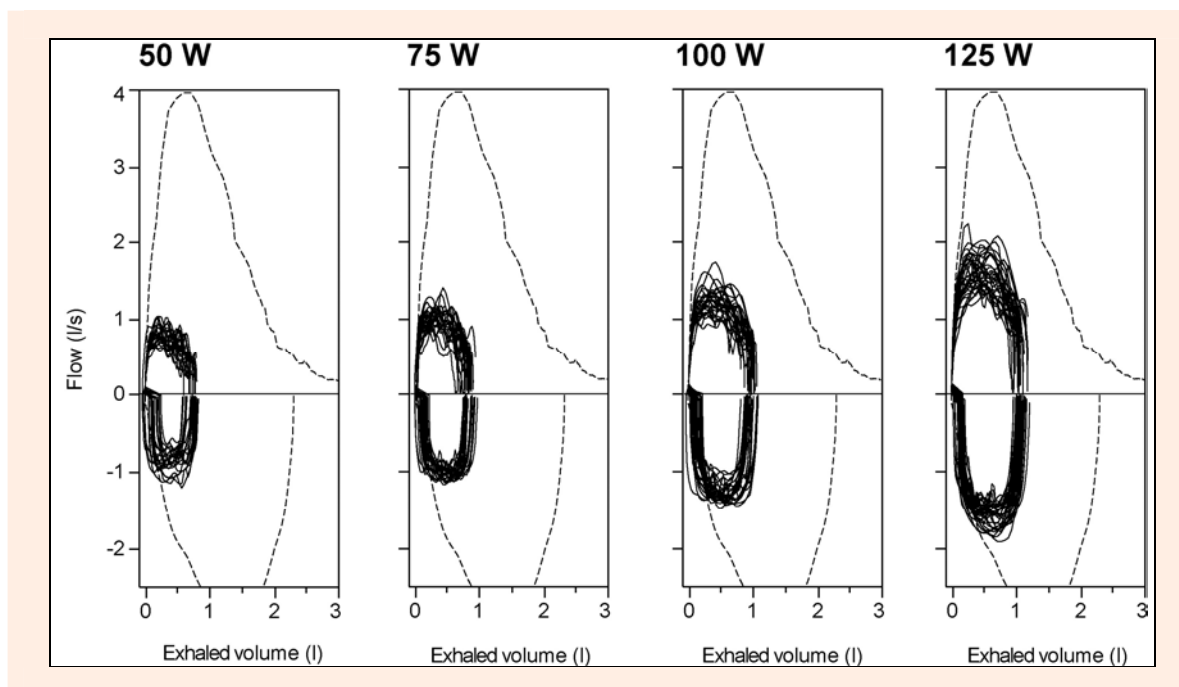


Figure 2. Flow-to-volume-curves at different exercise intensities during the exercise test (bicycle- ergometric up to 125W). The subject did not approach their forced ex- and inhalation taken at rest (dashed lines). Hence, a mechanical limitation to the ventilation during exercise could be excluded.

2005). Beaty and Hoffman (1999) found lower inspiratory flow rates after medialization thyroplasty. No modification of the breathing parameters was shown after fat injection in the vocal fold (Cantarella et al., 2006).

We are here describing an extraordinary achievement in an endurance form of athletics with a unilateral vocal fold paralysis for the first time. Although a marathon race is an endurance exertion without maximum acute strain on the respiratory system (McArdle et al., 2001), the sport medical examinations also showed no restriction at maximum exertion, neither expiratory nor inspiratory. An unilateral vocal fold paralysis is apparently not such a serious obstacle to the respiratory tract that one would have to reckon with a clear-cut respiratory deficit. Exercise testing of larger samples of patients with vocal fold paralysis should be performed concerning their capacity to endure exertion.

The question in the present case thus remains the causal connection between the paralysis and unspecific respiratory complaints. The laryngological examination speaks against an acute event. A possible cause of the vocal fold paralysis is the thoracotomy or the pleuritis in childhood; Due to the time lapse of over 40 years, this cannot be proven. The entire diagnostic spectrum excluded another organic cause for her respiratory complaints, so that we tend to assume a functional or psychosomatic nature. As the symptoms vanished spontaneously, no further proof of this can be offered.

Matthias Echternach¹✉, **Kai Röcker**², **Susan Arndt**³, **Daniel Schöbner**³ and **Bernhard Richter**¹

¹ Institute of Musicians' Medicine, Freiburg University Medical Center, ² Department of Sports Medicine, Freiburg University Medical Center, ³ Department of Otorhinolaryngology, Head and Neck Surgery, Freiburg University Medical Center

References

- Beaty, M.M. and Hoffman, H.T. (1999). Impact of laryngeal paralysis and its treatment on the glottic aperture and upper airway flow characteristics during exercise. *Otolaryngology Head and Neck Surgery* **120**, 819-823.
- Cantarella, G., Fasano, V., Bucchioni, E., Domenichini, E. and Cesana, B.M. (2003) Spirometric and plethysmographic assessment of upper airway obstruction in laryngeal hemiplegia. *Annals of Otolaryngology, Rhinology and Laryngology* **112**, 1014-1020.
- Cantarella, G., Fasano, V., Bucchioni, E., Maraschi, B. and Cesana, B.M. (2005) Variability of specific airway resistance in patients with laryngeal hemiplegia. *Annals of Otolaryngology, Rhinology and Laryngology* **114**, 434-438.
- Cantarella, G., Fasano, V., Maraschi, B., Mazzola, R.F. and Sambataro, G. (2006) Airway resistance and airflow dynamics after fat injection into vocal folds. *Annals of Otolaryngology, Rhinology and Laryngology* **115**, 810-815.
- Laccourreye, O., Papon, J.F., Kania, R., Menard, M., Brasnu, D. and Hans, S. (2003) Unilateral laryngeal paralyses: epidemiological data and therapeutic progress. *Presse Medicale* **32**, 781-786. (in French)
- McArdle, W.D., Katch, F.I. and Katch, V.L. (2001) *Exercise physiology. Energy, nutrition and human performance*. Philadelphia: Lippincott Williams & Wilkins.

✉ **Matthias Echternach, MD**

Institut of Musicians' Medicine, Freiburg University Medical Center, Breisacherstr. 60, 79106 Freiburg, Germany
E-mail: matthias.echternach@uniklinik-freiburg.de